

Long-term vertical changes of the anterior maxillary teeth adjacent to single implants in young and mature adults

A retrospective study

J. P. Bernard¹, J. P. Schatz²,
P. Christou², U. Belser³ and
S. Kiliaridis²

Departments of ¹Oral Surgery;
²Orthodontics; ³Prosthodontics, University of
Geneva, School of Dental Medicine, Geneva,
Switzerland

Bernard JP, Schatz JP, Christou P, Belser U, Kiliaridis S. Long-term vertical changes of the anterior maxillary teeth adjacent to single implants in young and mature adults. A retrospective study. *J Clin Periodontol* 2004; 31: 1024–1028. doi: 10.1111/j.1600-051X.2004.00574.x. © Blackwell Munksgaard, 2004.

Abstract

Aim: To evaluate the effects of the tooth eruption process on the position of teeth adjacent to implant-borne restorations in adult patients compared to patients in their late adolescence.

Subject and Methods: The sample included 28 patients divided into two groups. A “young adult” group consisting of 14 patients, aged from 15.5 to 21 years, and a “mature adult” group consisting of 14 patients, aged from 40 to 55 years. All patients presented missing anterior teeth, requiring insertion of 40 implant fixtures (16 central incisors, 12 lateral incisors, 12 canines). The implants were of the Straumann Dental Implant System, clinically and radiologically re-evaluated 1 year or more after the surgical procedure (mean interval = 4.2 years). Assessment of the eruption of the adjacent teeth was performed using the implant as a stable point of reference: measurements of the different reference points were compared after implant placement and at follow-up examination.

Results: In the “young adult” group, all patients showed infra-occlusion of the implant-supported crowns: the vertical step measured on radiographs varied between 0.1 and 1.65 mm. In the “mature adult” group, all patients showed a vertical difference between the teeth adjacent to the implant-supported crown and the implant: the measured step ranged from 0.12 to 1.86 mm. No difference was found in the amount of vertical eruption between male and female patients, nor according to localization of the implant.

Conclusion: Mature adults can exhibit major vertical steps after anterior restorations with osseointegrated fixtures to the same extent as adolescents or “young adult” individuals with residuous growth potential.

Key words: adult patients; alveolar and skeletal growth; ankylosis; implants; tooth eruption

Accepted for publication 17 December 2003

The absence of anterior permanent maxillary teeth following trauma or congenital aplasia is a difficult therapeutic problem which may be corrected by orthodontic or prosthetic means. The need for long-term maintenance of “conventional” fixed partial bridges and their possible detrimental impact on periodontal health are factors generally favoring orthodontic correction of the

problem in young patients (Nordquist & McNeill 1975, Dietschi & Schatz 1997).

Implant-supported crowns are now considered as the least invasive treatment in cases of missing anterior teeth with optimal esthetic outcome. The use of implants in growing individuals has been studied by clinical (Ödman et al. 1988, Thilander et al. 1994, 1999) and animal studies (Ödman et al. 1991,

Thilander et al. 1992, Sennerby et al. 1993) showing that implants behave like ankylosed teeth and do not follow the changes of the alveolar processes due to continuous eruption of adjacent teeth. Moreover, the osseointegrated fixtures will not be able to be displaced in the sagittal and transverse dimensions during growth of the jaws (Thilander et al. 1994, Iseri & Solow 1996).

The non-eruption potential of the implants and, consequently, of the implant-supported restorations, in young individuals is likely to cause a discrepancy in the occlusal plane. This discrepancy has been extensively documented and may result in clinical infraocclusion of the implant-supported crowns (Thilander et al. 1994, 1999). This was the main contraindication to the use of implants in growing individuals. However, Thilander et al. (1999) reported similar observations in three adult cases, and since then, many questions remain open concerning the correlation between the effect of the continuous teeth eruption and the position of teeth adjacent to implant restorations: are the adult patients exposed to the same risk, and if so, to the same extent?

The aim of this study was to assess the effect of the continuous tooth eruption process on the position of teeth adjacent to implant-borne restorations of patients in mature adulthood compared to changes appearing in patients in their late adolescence.

Subjects and Method

One hundred and eighty-two patients requiring implant surgery for late prosthetic rehabilitation in the anterior area were treated in the Oral Surgery Department between September 1990 and December 1998.

From the initial sample, two different groups were created: a "young adult group" incorporating all patients from the age range 15.5–21 years, only treated for replacement of single upper anterior teeth, and a "mature adult" group, including all the patients from the age range 40–55 years of age, and also treated only for replacement of single upper anterior teeth.

Hence, 28 patients – 10 males and 18 females – were selected: all the patients presented missing anterior teeth following trauma or congenital aplasia, requiring insertion of 40 implant fixtures (16 central incisors, 12 lateral incisors, 12 canines) for late prosthetic rehabilitation. Divided according to their age, the two groups showed the following characteristics:

The *young adult group* (mean age at surgery 18.4 years, age range 15.5–21 years) consisted of 14 young patients: five males and nine females. The patients of this group received 21 single implant-supported crowns as replacement of anterior missing teeth (10 central incisors, six lateral incisors, four canines). In

seven patients, two fixtures were inserted for the replacement of two anterior teeth, one on each side (left–right).

The *mature adult group* (mean age at surgery 43.6 years, age range 40–55 years) consisted of 14 mature adult patients (five males and nine females) who had received 19 anterior implants (six central incisors, five lateral incisors, eight canines). In five patients, two fixtures were inserted for the replacement of two anterior teeth, one on each side (left–right).

One tooth adjacent to the implant was used as the control tooth, for evaluation of possible eruption processes. During the whole evaluation period, control teeth had to remain restoration free and periodontally healthy, according to the following criteria: Plaque Index (PI) and Gingival Index (GI) scores <1, absence of pockets >3 mm, no bleeding on probing (BOP) and no radiographic evidence of alveolar bone loss.

Finally, the continuity of periodontal ligament on radiographs was evaluated in order to exclude replacement resorption processes.

In anamnestic records, no patients showed systemic diseases or long-term pharmacological treatment. To be included in the implant surgery clinic, all patients followed a dental hygiene professional maintenance care program, including instructions on oral hygiene, with regular recall appointments at 15 days and 3 months post-surgery, and thereafter every year.

Implant placement

The surgical procedure was performed by the same experienced oral surgeon (J. P. B. – Department of Oral Surgery and Oral Pathology). The implants and the titanium abutments used in the second phase of treatment were of the Straumann Dental Implant System (Institute Straumann AG, Waldenburg, Switzerland). The latency period (time of the healing process required for the stabilization of the implants) was reduced to 12 weeks, according to the University of Geneva protocol. The abutment connection was performed with a special dynamometric key (ITI Straumann Dental Implant System), according to the manufacturer, at 35 N/cm.

Clinical and radiological assessment

The follow-up registration took place 1 year or more after the surgical proce-

dure (mean interval, 4.2 years; range, 1 year 8 months to 9 years 1 month).

The examination included:

1. A clinical examination to exclude the presence of peri-implantitis and to evaluate stability. The clinical evaluation included measurement of probing pocket depth (PPD), and assessment of the Modified Plaque Index (mPI) and of the GI (Mombelli et al. 1987). The presence or absence of suppuration (SI), Bop, as well as the lack of evidence of continuous peri-implant radiolucency, were also checked in order to exclude the presence of peri-implantitis. Assessment of the mobility of each single implant was made either by direct measurement on implant, or later on crown restoration, according to Mombelli et al. (1987).
2. A radiographic examination for assessment of the implant insertion areas. Intra-oral peri-apical radiographs were taken with the "parallel technique" and allowed comparison to peri-apical radiographs were taken immediately following surgery. A dental X-ray machine (Siemens Heliodent MD, Siemens Aktien-gesellschaft, Munich, Germany) and KODAK EKTASPEED Plus Intraoral Dental Film (Eastman Kodak Company, Rochester, NY, USA) were exposed and developed according to the instructions of the manufacturer.

The intra-oral radiographs were digitized by means of a Hewlett-Packard HP C2520A scanner (Hewlett-Packard, Palo Alto, CA, USA) in 600 dots per inch (dpi) analysis. The computer used for the data elaboration was equipped with a 17 in ViewSonic screen (ViewSonic 17 GS, ViewSonic Co, Walnut, CA, USA), a Matrox Millennium graphics card (Matrox Electronic Systems, Dorval, Quebec, Canada) and the screen analysis was set to 800 × 600. The evaluation of dimensions was performed with the Osiris software for Windows (medical imaging software, version 3.6, Digital Imaging Unit, University Hospital of Geneva). Assessment of the eruption of the adjacent teeth was performed using the implant as a stable point of reference: after selection of different reference points on implants and adjacent teeth, data were obtained by comparing the measurements after implant placement and at follow-up examination. The method is described in Fig. 1.

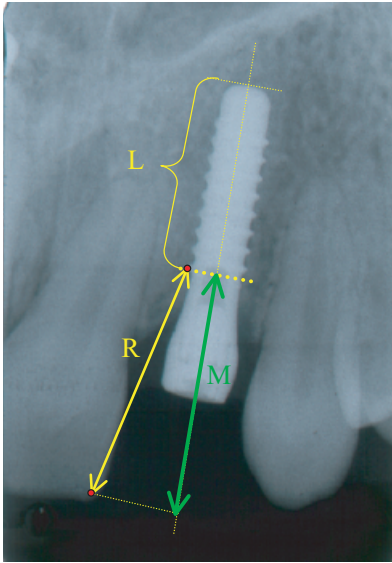


Fig. 1. Assessment of the eruption of the adjacent teeth: (a) evaluation of the image distortion by measuring the length of the implant (= L) as it appears on the radiography compared to the real length of the implant; (b) selection of an easily identifiable point of reference (= •) located on the cervical thread of the implant; (c) selection of a point of reference located on the tooth adjacent to the implant (intersection point between incisal border and mesial or distal side of the tooth); (d) measurement of the distance (= R) between the projection of the two selected points on the longitudinal axis of the implant (T0); (e) measurement, on the radiograph taken at the follow-up examination (T1), of the distance between the projection of the two selected points on the longitudinal axis of the implant (= M); and (f) measurement of the amount of vertical movement of the adjacent tooth, by comparing the data obtained at T0 and T1.

Statistical analysis

All measurements were repeated with an interval of 1 month by the same observer (P. C.) to assess the error of method involved. A high reproducibility of the measurements was found (error 2.26%). For the analysis of the results, Mann-Whitney U-test was performed between the two groups to assess the level of significance of the discrepancies observed. Multiple regression analysis was performed for both groups to assess the relationship of the discrepancy observed with the age at placement and the observation period.

Results

Control teeth remained periodontally healthy throughout the whole evaluation

period (data not shown). No signs of peri-implantitis were observed in any of the implants by clinical and radiographic measurements (data not shown).

Stability of the inserted implants together with a good esthetic outcome of the rehabilitation was reported for all the patients. However, in most of the patients of both groups, a change in vertical position of the implant-supported crown was observed (Fig. 2).

Young adult group

In seven patients, two fixtures were inserted for replacement of two anterior teeth, one on each side.

In relation to the adjacent teeth, all patients of the sample showed infra-occlusion of the implant-supported crown. The vertical step measured on radiographs varied between 0.10 to 1.65 mm (mean = 0.69 mm), with only seven cases showing greater variations than the mean (Table 1). The vertical changes observed could already be noticed in some patients after short evaluation period, namely 13 months.

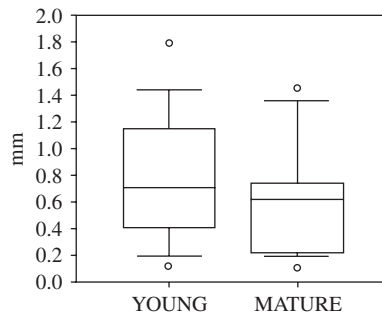


Fig. 2. Vertical changes of anterior teeth adjacent to implant in both samples (mm).

Table 1. Sample description (age at placement, localization of the implant, vertical step for each implant, mean value in subjects with two implants)

Subjects	Age	Implants		Follow-up period	Discrepancy (mm)		Mean
C. A.	51.7	12	21	6.0	0.76	0.61	0.685
K. I.	56.7	11	23	2.1	0.64	0.58	0.61
C. M.	40.7	13	23	8.7	1.86	0.97	1.415
H. J. M.	42.10	11	21	3.7	0.70	0.59	0.645
R. J.	43.9	13		3.3	0.12		
M. F.	42.11	22		6.9	0.22		
L. E.	43.9	22		3.0	0.20		
G. C.	43.6	12		3.5	1.32		
C. D.	49.1	13		7.9	0.21		
F. G.	44.2	12	21	4.6	0.68	0.54	0.61
G. C.	41.5	13		3.4	0.53		
R. J.	43.5	13		3.0	0.79		
G. D. M. M.	38.6	23		2.1	0.63		
N. F.	40.2	21		1.3	0.74		

Mature adult group

In five patients, two fixtures were inserted to replace two anterior teeth, one on each side. Most of the patients showed vertical difference between the teeth adjacent to the implant-supported crown and the implant itself. The measured step varied from 0.12 to 1.86 mm (mean = 0.67 mm). In this sample only five cases showed greater variations than the mean (Table 2). The vertical changes observed could already be detected in some patients after short evaluation periods, such as 15 months.

No difference was found between males and females in the amount of vertical eruption of adjacent teeth (Fig. 3).

We can also observe that no difference existed in the amount of vertical eruption between the implant and the adjacent teeth at various localizations of the implant (canine, lateral, or central incisor region) (Fig. 4).

Multiple regression analysis of the data from both groups was performed. The independent variable was the observed discrepancy while the dependent variables were the age groups (dummy variable), and time between fixture placement and follow-up examination. For the patients with two fixtures, the mean of the measured discrepancy was used giving only one measure of discrepancy per individual. The relation between the vertical discrepancy to the age of the groups and the period of observation was very low (R = 0.024), showing a non-statistically significant importance of the variables.

Discussion

The high incidence of dento-alveolar traumatic injuries and the increasing

Table 2. Sample description (age at placement, localization of the implant, vertical step for each implant, mean value in subjects with two implants)

Subjects	Age	Implants	Follow-up period	Discrepancy (mm)	Mean
K. F.	24.1	21	9.1	0.33	
P. C.	16.11	11	6.7	1.15	
M. C.	19.10	13 23	1.6	0.68	0.3
B. E.	19.10	12 22	2.4	1.65	0.84
S. C.	15.8	12 22	8.3	0.8	0.88
I. M.	19.9	23	5.3	1.76	
F. E.	17.8	12 22	1.9	0.1	0.3
G. D.	17.2	12 21	1.1	0.48	1.38
S. I.	15.4	21	2.8	1.02	1.02
M. S.	18.0	21	1.8	0.13	
N. C.	19.2	23	5.3	0.82	
V. J.	20.1	21	6.0	0.45	
V. V.	19.0	11 21	5.5	0.38	0.44
	17.10	11 21	3.4	0.58	0.61

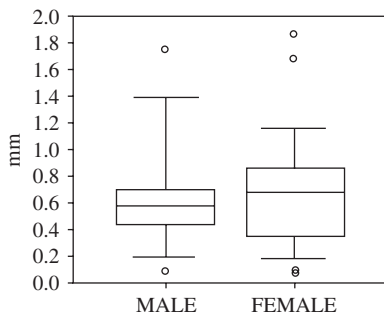


Fig. 3. Vertical changes of anterior teeth adjacent to implant according to gender (mm).

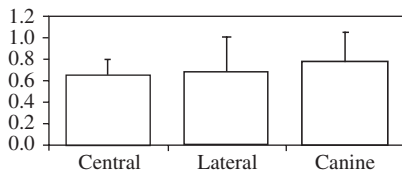


Fig. 4. Vertical changes of anterior teeth adjacent to implant according to localization of the implant (mm).

concern of patients for esthetics in cases of congenital absence of anterior teeth have raised some debate about current restorative modalities. The main treatment options for anterior tooth replacement are adhesive fixed partial bridges, conventional fixed partial bridges and implant-supported crowns (Dietschi & Schatz 1997). Some authors also suggested the use of autotransplantations in selected cases (Slagsvold & Bjercke 1978). Implants and adhesive prostheses are nowadays preferred because they represent more conservative approaches as compared to traditional fixed prosthodontics. However, as osseointegrated fixtures do not adapt to eruptive processes or growth changes, their use in young individuals may lead to clinical

infra-occlusion and compromise the esthetic rehabilitation of missing teeth in the anterior area. Some authors even described a reduction of alveolar height at the teeth adjacent to the implants, which could possibly lead to periodontal defects, particularly in upper lateral incisor area if distance between implant and adjacent teeth is too short (Thilander et al. 2001). Most authors recommend to delay the use of implant-borne restorations in the anterior area until skeletal growth is completed, some of them precisizing that implant placement should be delayed until age 15 for girls and age 18 for boys (Cronin et al. 1994).

This assumption could not be substantiated by the results of the present study, showing that infraocclusion occurs also in patients who had received single implants in adult ages. In some of the cases, the infra-occlusion, due to the continuous vertical eruption of adjacent teeth, created a noticeable variation in the occlusal plane. Interestingly, the findings of our study show that the continuous eruption process of the adjacent teeth in the mature adulthood may be, in some individuals, as large as that observed in younger patients. The statement that the eruption potential may be larger in young adult individuals was not fully confirmed by our results. However, it should be stressed that the present sample did not include growing individuals of the pre-pubertal and pubertal growth stage, since the alveolar vertical changes were expected to be very large in these cases.

A previous study on young patients has shown that there is a continuous eruption of the teeth adjacent to an implant, proportional to the residual

growth of the individual (Thilander et al. 1994). In this 3-year follow-up study, infra-occlusion was recorded in most of the patients: the larger the residual growth, the bigger the infra-occlusion of the implant-supported restoration. It has to be stressed however, that the mean changes in the anterior area were small in most of the cases (mean 0.46 mm). Our results seem in agreement with the findings of Thilander et al. (1994, 1999, 2001). An eruption of adjacent teeth was recorded in all the patients (mean = 0.718), matching the results of Thilander's group (1994), even though the mean age of the "young group" sample at the time of fixture placement was 18.4 years instead of 15.4 years in Thilander's sample. No difference was observed in the amount of eruption of the adjacent teeth in both samples, and also no significant difference was found looking at the localization of the implants.

The maxilla moves during growth in all three planes of space (Thilander 1995): as the maxilla follows its growth pattern downward and forward, the alveolar process undergoes considerable remodeling in anteroposterior, transversal, and vertical directions. The major portion of maxillary growth and remodeling takes place in the vertical direction: natural teeth with normal periodontal ligament tend to adapt to such tissue remodeling, which continues until late adolescence (Sarnäs & Solow 1980, Björk & Skieler 1983). On the contrary, osseointegrated implants remain stationary in the surrounding bone and do not move or adapt to eruptive processes or to growth changes.

The eruption of the adjacent teeth can be attributed to the continuous activity of the periodontal ligament (Berkovitz 1971), while the major part of the maxillary growth has usually been completed at the age of 15 for the girls and 1 or 2 years later for the boys. The bone activity observed on the maxilla after this age is mainly related to bone remodeling processes that may continue until late adulthood (Forsberg et al. 1991). Other studies (Forsberg et al. 1991, Ödman et al. 1991, Sennerby et al. 1993) already confirmed that many changes occur in the sagittal and the transversal dimensions which have not yet been quantified, even though some authors questioned their possible impact after the age of 25 years (Oesterlé & Cronin 2000).

These conclusions were stressed in a recent follow-up study by Thilander et al.

(1999, 2001) based on the observation of some patients of the first study, followed for 8 years: the mean vertical step increased this time from 0.46 to 0.95 mm, with large inter-individual variations. That following study revealed that infra-occlusion occurred in three adult patients who had received anterior single implants restorations. In some of the cases the infra-occlusion created a noticeable variation in the occlusal plane and a serious esthetic impairment. Our study fully documented clinical infra-occlusion of implant-borne restorations in mature adults: the results showed similar observations in late adolescents and adult patients, a vertical step of the same extent, detected in both groups after short evaluation period. Even if larger vertical steps have been observed in the adolescent groups, the number of patients showing larger deviation than the mean was similar in both groups, while no clear factors could be stressed to explain such differences between individuals.

However, many factors can interfere with the process of eruption of teeth adjacent to osseointegrated fixtures (i.e. pre-prosthetic orthodontic movements, periodontal status). Therefore prospective clinical trials would help to clarify the influence of continuous teeth eruption processes and craniofacial growth mechanisms on these restorations.

Conclusion

The use of osseointegrated implants for the prosthetic rehabilitation of anterior missing teeth is nowadays a common treatment modality. However a clinician has to keep in mind that the implant behaves as an ankylosed tooth and thus, never follows the eruption of the adjacent teeth. This specificity, often addressed in studies dealing with young individuals with residuous growth potential, has been shown to result in major esthetic impairment in anterior implant-borne restorations.

However, and even if in most adult patients the effect of adult residual growth or aging alterations may be small, the results of our study support the assumption that mature adults can also exhibit major vertical steps after anterior restorations with osseointegrated fixtures.

Other studies are therefore needed to evaluate the association of clinical infra-occlusion secondary to growth or aging processes with other factors such as loss of marginal bone support, and

their possible impact on treatment procedure strategies in cases with missing anterior teeth.

Acknowledgments

The authors wish to thank Dr. C. Giannopoulou and Dr G. Cimasoni for their review and comments.

References

- Albrektsson, T., Brånemark, P. I., Hansson, H. A. & Lindstrom, J. (1981) Osseointegrated titanium implants. Requirements for ensuring a long-lasting, direct bone-to-implant anchorage in man. *Acta Orthopædica Scandinavica* **52**, 155–170.
- Berkovitz, B. K. (1971) The effect of root transection and partial root resection on the unimpeded eruption rate of root incisors. *Archives of Oral Biology* **16**, 1033–1043.
- Brånemark, P. I., Hansson, B. O., Adell, R., Breine, U., Lindstrom, J., Hallen, O. & Ohman, A. (1977) Osseointegrated implants in the treatment of the edentulous jaw. Experience from a 10-year period. *Scandinavian Journal of Plastic Reconstructive Surgery* **16** (Suppl.), 1–132.
- Björk, A. & Skieler, V. (1983) Normal and abnormal growth of the mandible. A synthesis of longitudinal cephalometric implant studies over a period of 25 years. *European Journal of Orthodontics* **5**, 1–46.
- Cochran, D. L., Buser, D., ten Bruggenkate, C. M., Weingart, D., Taylor, T. M., Bernard, J. P., Peters, F. & Simpson, J. P. (2002) The use of reduced healing times on ITI implants with a sandblasted and acid-etched (SLA) surface: early results from clinical trials on ITI SLA implants. *Clinical Oral Implants Research* **13**, 144–153.
- Cronin, R. L., Oesterle, L. J. & Ranly, D. M. (1994) Mandibular implants and the growing patient. *International Journal of Oral and Maxillofacial Implants* **9**, 55–62.
- Dietschi, D. & Schatz, J. P. (1997) Current restorative modalities for young patients with missing anterior teeth. *Quintessence International* **28**, 231–240.
- Forsberg, C. M., Eliasson, S. & Westergren, H. (1991) Face height and tooth eruption in adults – a 20-year follow-up investigation. *European Journal of Orthodontics* **13**, 249–254.
- Iseri, H. & Solow, B. (1996) Continued eruption of maxillary incisors and first molars in girls from 9 to 25 years, studied by the implant method. *European Journal of Orthodontics* **18**, 245–256.
- Mombelli, A., Van Oosten, M. A. C., Schürch, E. & Lang, N. P. (1987) The microbiota associated with successful or failing osseointegrated titanium implants. *Oral Microbiology and Immunology* **2**, 145–151.
- Nordquist, G. G. & McNeill, R. W. (1975) Orthodontic v/s restorative treatment of the

congenitally absent lateral incisors-Long-term periodontal and occlusal evaluation. *Journal of Periodontology* **46**, 139–143.

- Ödman, J., Grondahl, K., Lekholm, U. & Thilander, B. (1991) The effect of osseointegrated implants on the dento-alveolar development. A clinical and radiographic study in growing pigs. *European Journal of Orthodontics* **13**, 279–286.
- Ödman, J., Lekholm, U., Jemt, T., Brånemark, P. I. & Thilander, B. (1988) Osseointegrated titanium implants – a new approach in orthodontic treatment. *European Journal of Orthodontics* **10**, 98–105.
- Ödman, J., Lekholm, U., Jemt, T. & Thilander, B. (1994) Osseointegrated implants as orthodontic anchorage in the treatment of partially edentulous adult patients. *European Journal of Orthodontics* **16**, 187–201.
- Oesterle, L. J. & Cronin, R. J. (2000) Adult growth, aging, and the single-tooth implant. *International Journal of Oral and Maxillofacial Implants* **15**, 252–260.
- Sarnäs, K. V. & Solow, B. (1980) Early adult changes in the skeletal and soft-tissue profile. *European Journal of Orthodontics* **2**, 1–12.
- Sennerby, L., Ödman, J., Lekholm, U. & Thilander, B. (1993) Tissue reactions towards titanium implants inserted in growing jaws. A histological study in the pig. *Clinical Oral Implants Research* **4**, 65–75.
- Slagvold, O. & Bjerke, B. (1978) Applicability of autotransplantations in cases of missing upper anterior teeth. *American Journal of Orthodontics* **74**, 410–421.
- Thilander, B. (1995) Basic mechanisms in craniofacial growth. *Acta Odontologica Scandinavica* **53**, 144–151.
- Thilander, B., Ödman, J., Grondahl, K. & Friberg, B. (1994) Osseointegrated implants in adolescents. An alternative in replacing missing teeth? *European Journal of Orthodontics* **16**, 84–95.
- Thilander, B., Ödman, J., Grondahl, K. & Lekholm, U. (1992) Aspects on osseointegrated implants inserted in growing jaws. A biometric and radiographic study in the young pig. *European Journal of Orthodontics* **14**, 99–109.
- Thilander, B., Ödman, J. & Jemt, T. (1999) Single implants in the upper incisor region and their relationship to the adjacent teeth. An 8-year follow-up study. *Clinical Oral Implant Research* **10**, 346–355.
- Thilander, B., Ödman, J. & Lekholm, U. (2001) Orthodontic aspects of the use of oral implants in adolescents: a 10-year follow-up study. *European Journal of Orthodontics* **23**, 715–731.

Address:

Jean-Paul Schatz

Department of Orthodontics

University of Geneva Dental School

19, rue Barthélemy-Menn

1205 Geneva

Switzerland

E-mail: jean-paul.schatz@medecine.unige.ch