

Adult Growth, Aging, and the Single-Tooth Implant

Larry J. Oesterle, DDS, MS¹/Robert J. Cronin Jr, DDS, MS²

Single-tooth implants are an increasingly popular method for replacing single teeth. While the effects of growth on implants in children have been well documented, the changes that occur in adults have not been studied with respect to single-tooth implants. It has been assumed that adults are stable and do not change; however, research in the last few years has indicated that adults do change with aging, and adult growth does occur. The changes in adults occur over decades rather than rapidly, as seen in children. Aging changes are readily apparent in the soft tissues of the face and create dramatic changes. Changes in the jaws and teeth occur as a result of continued, slow growth, in contrast to the aging effects seen in soft tissues. Growth changes occur in the arches and result in adaptive changes in the teeth over time, both vertically and horizontally, and in alignment. These dental changes may result in a lack of occlusion vertically or malposition of adjacent natural teeth relative to the implant crown. Clinicians may be well advised to observe and report these changes and warn patients that changes can occur over the service life of the implant-supported crown. These changes may require maintenance adjustments or possible remaking of the implant crown as a result of adult growth, wear, or the esthetic changes of aging. (INT J ORAL MAXILLOFAC IMPLANTS 2000;15:252-260)

Key words: adult growth, aging, single-tooth implant

Osseointegrated implants have become a routine restorative procedure as a result of extensive long-term studies by Adell et al¹ and Albrektsson² of completely edentulous patients. The natural extension of this initial work is the use of implants to replace teeth in the partially edentulous patient and for single-tooth replacements. The use of a single-tooth implant-supported prosthesis provides esthetic and dental tissue conservation advantages, by avoiding the preparation of caries- and restoration-free abutment teeth. Resin-bonded or Maryland prostheses are another alternative; however, their high failure rate makes them a less viable alternative.³ The single-tooth implant is reported to

be highly effective, with success rates of 96% at 5 years and 89% at 10 years.⁴ Other studies confirm the effectiveness of the single-tooth implant-supported prosthesis but are of shorter duration.^{5,6} Reports^{7,8} of immediate placement of an implant after single-tooth extraction, reducing the otherwise lengthy preparation time, have further spurred interest in single-tooth implants. For all of the above reasons, there is an increase in the use of the single-tooth implant-supported prosthesis.^{3,9,10}

Single-tooth implants, however, are not without their problems. Kucey¹¹ reported a higher incidence of single-tooth replacement implant failure than with other types of implants. The most common area (70%) for single-tooth implant use is in the anterior maxilla.¹² However, this can be a difficult area in which to use a single-tooth implant because of esthetic demands, occlusal limitations, and limited space and bone volume. In addition, natural teeth that are adjacent to a single-tooth implant may not respond periodontally as favorably as natural teeth that are separated from implants by an edentulous ridge.^{6,10}

Single-tooth implants in growing individuals are problematic because the implant behaves like an ankylosed tooth.^{13,14} The inability of the implant to

¹Associate Professor and Chair, Department of Growth and Development, University of Colorado Health Sciences Center, Denver, Colorado.

²Professor and Graduate Program Director, Department of Prosthodontics, University of Texas Health Science Center at San Antonio, San Antonio, Texas.

Reprint requests: Dr Larry J. Oesterle, Department of Growth and Development, Campus Box C284, University of Colorado Health Sciences Center, 4200 East Ninth Avenue, Denver, CO 80262. Fax: (303) 315-5206. E-mail: larry.oesterle@UCHSC.edu

adapt to maxillomandibular and alveolar growth, in the manner of adjacent natural teeth, dramatically affects the position of the single-tooth implant relative to adjacent teeth. Growth can result in poor implant position, burying of the implant in bone, or implant loss. Thus, the single-tooth implant, if placed too early, can act as a focus of a developing malocclusion. This effect was observed in implants placed in growing pigs¹⁵ and is further supported by case reports of adverse changes associated with implants in human adolescents.^{16,17}

Change (growth) in adults has been totally discounted, assuming that growth ends in early adulthood and ceases to be a factor in adults. A lack of significant growth in adults continues to be held as a truth by many and is supported by the ambiguity of the results of cross-sectional studies. It was only with well-controlled longitudinal studies of adults, such as those by Behrents¹⁸ and others,^{19,20} that the myth of "adults don't grow" was put to rest. Although the effects of adult growth are very slow and measured in terms of decades, changes do occur and have a long-term effect on a single-tooth implant adjacent to natural teeth.

The purpose of this paper is to review the research on changes due to growth and aging in the adult face, arches, and dentition and relate these to the effect of those changes on a single-tooth implant prosthesis. To place adult growth in its proper context as a part of aging, the facial, dental, and bony changes that take place in children will be discussed and related to the continuation of the growth process into adulthood. As single-tooth implant-supported prostheses exceed 20 years of service, growth-related changes will begin to occur. Knowledge of adult growth effects therefore become important to recognize and explain, and any positional anomalies can then be treated.

FACIAL CHANGES

Facial changes occur in the adult with growth and aging, but the changes are not as dramatic as in the child. In the child the face grows from beneath the cranium, developing relatively more than the cranium. While the cranium is nearly young-adult size by 7 or 8 years, the face continues to grow significantly in a downward and forward direction. The face grows from the very convex, mandibular retrognathic profile of the infant to the nearly straight profile of the adult. Much of this change occurs with the greater downward and forward growth of the mandible relative to the maxilla, particularly during adolescence. Greater mandibular growth, combined

with the increasing size of the frontal sinus and nose, results in the more angular, straighter profile of the adult.

In the growing child, the rate and timing of growth differ between different parts of the face and between males and females. For example, the majority of lip growth is completed by 15 years, while the nose grows in greater amounts and may grow significantly beyond 18 years.²¹ While females complete the majority of their adolescent growth by 15 years, males continue to grow into their twenties. Between 15 and 25 years, males increase their standing height by 15%, their maxillary depth by 20%, and their mandibular depth by 26%, while positioning their mandible forward by 30% and changing their maxillomandibular relationship by 33%.²² This has implications both in planning treatment and in evaluating adult growth studies. Studies of adult growth that include males younger than 25 years show more growth changes than those that include only older males or only females. Females can be treatment-planned as adults earlier than males because of later male growth.

This is not to imply that females do not change after the age of 15. Most females change very little in early adulthood (17 to 20 years), but appear to grow again in their early 20s and 30s. Since these are the usual childbearing years, this resurgence of female growth may be associated with the growth hormones present during pregnancy, suggesting a possible "female post-fertilization growth acceleration" not seen in males. Growth direction also differs between the sexes, with males growing in the same direction as in adolescence and females tending to grow more vertically.¹⁸ In both males and females, as much soft tissue change has been reported between 25 and 42 years as occurs between 18 to 25 years.²³ Adult growth does occur, and in significant amounts, but slowly, over a long period of time.

Dramatic soft tissue changes take place with increasing age. Some of the facial changes are the result of adult growth, while other changes occur from the effects of gravity and aging on facial skin, which becomes progressively thinner, drier, and less elastic.²⁴ Other skin changes occur as a result of individual responses to the effects of ultraviolet radiation and smoking,²⁵ histologic changes related to photoaging (sun) effects,²⁶ and weight increases.^{18,27} Thus, in considering adult growth, the effects of increased body weight, gravity, sun, and histologic changes must be considered.

Overall, faces appear to get larger with aging and adult growth,¹⁸ with some facial areas changing considerably. Ears and noses grow larger, foreheads

become wrinkled, and hairlines recede as a part of the aging process.²⁸⁻³⁰ Eyebrows become more prominent and often descend below the bony ridge, giving an angry look to the aging face.^{24,29} This is further emphasized by gravitational displacement of the cheeks, producing the gaunt look of old age.²⁵ Of these changes, the only one associated with actual growth is the nose, which becomes longer and more angular.^{18,31,32}

Lip changes also occur with aging. Upper lip length is completed by 15 years of age in both males and females, with males increasing upper and lower lip length more (7 mm) than females (3 mm) during adolescence.²¹ Upper lip length continues to increase during adulthood, resulting in a 1.0 mm decrease in maxillary incisor exposure by 42 years.²³ This increase appears to occur at the same rate as the downward growth of the nose tip. Increased upper and lower lip length, decreased maxillary incisor exposure, increased mandibular incisor visibility, and decreased lip vermilion exposure all occur with aging.^{18,30} Relative to the nose and chin, lip prominence and thickness also decrease with age in both males and females.¹⁹ Many of these changes can be related to adult growth.

BONY CHANGES

Underlying the soft tissue changes, skeletal changes also occur in adults (Fig 1). The skeletal changes appear more like the growth seen during adolescence than the drooping, sagging changes seen in the soft tissue. Since nearly all of the facial sutures close in early adulthood, the skeletal growth during adulthood must take place as a result of remodeling.¹⁸ Facial height increases both anteriorly and posteriorly, with a greater increase in the lower than in the upper face, resulting in a significant change in the area of the dentition.^{20,23,33} This increase in facial height totals nearly 3 mm between 17 and 80 years, with the increase continuing into the eighties.¹⁸ In males, posterior facial height (posterior maxilla and mandible) increases more than anterior facial height, while females have nearly equal increases in anterior and posterior facial height.²³ Multiple tooth loss resulting in substantial dental reconstruction results in less anterior facial growth, probably the result of an alteration in mandibular position.¹⁸ While multiple tooth loss decreases the amount of vertical growth, the effects of single tooth loss are probably minimal.

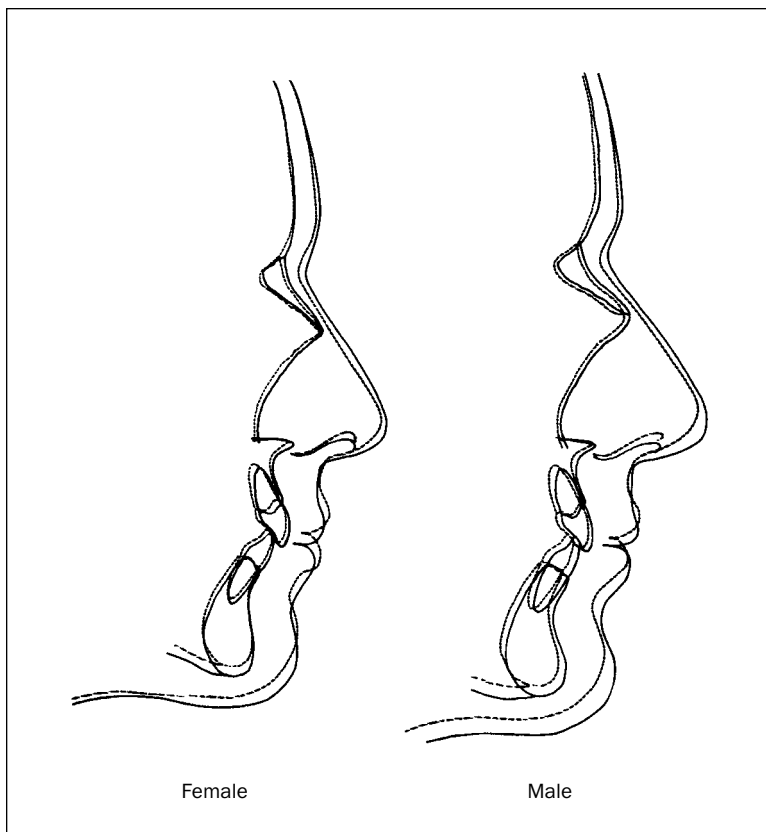


Fig 1 Composite soft tissue profile and skeletal changes seen in adult males and females with aging, from a young adult to old age.¹⁸ Dotted lines = young adult; solid lines = old age. (Reprinted with permission.)

Skeletal changes in the maxilla and mandible are important to the single-tooth implant, because as the arches grow apart, the teeth erupt and move into the space created (Fig 2a). During adulthood, the maxilla and the mandible continue to grow downward and forward, away from the cranial base.^{18,19} While the average maxillary change is small (1 mm) over a 60-year period, some individuals demonstrate as much as a 5-mm change. Changes in mandibular position and length also occur with increasing age.^{18,34,35} The symphysis moves downward and forward throughout all age spans, with males growing more than females. While in males the skeletal chin grows in a more forward direction, creating a more prominent bony chin (Fig 2b), in females, it grows mostly downward (Fig 2c). Hence in males, more horizontal skeletal growth occurs, while in females more vertical growth occurs with a backward rotation of the mandible, increasing skeletal vertical dimension. Males demonstrate more vertical growth in the posterior area of the maxilla and mandible, resulting in a flatter angle between the anterior cranial base and the lower border of the mandible, further increasing chin prominence. No change is seen in the position of the condyle relative to the cranial base structures, implying that there is little or no change in the position of the glenoid fossa during adult growth.¹⁸

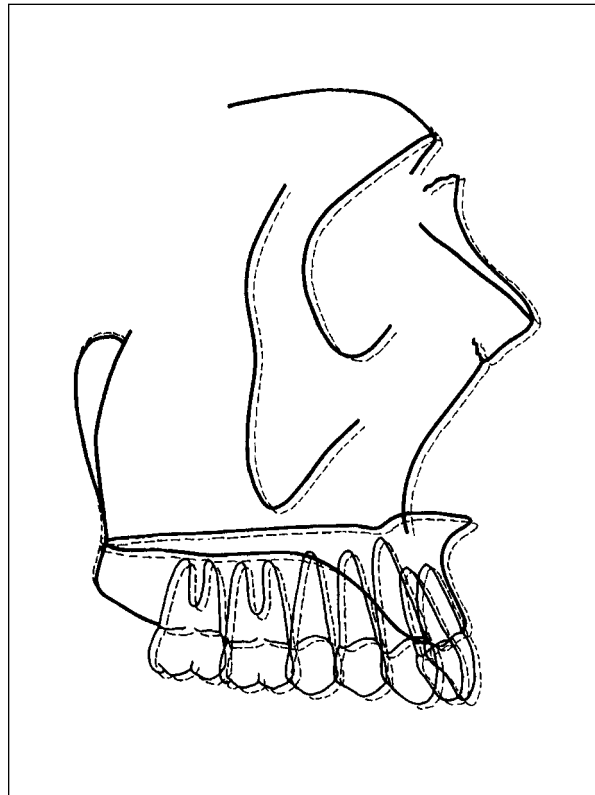


Fig 2a Maxillary positional changes occurring during adult growth, which are nearly identical for males and females.¹⁸ (Reprinted with permission.)

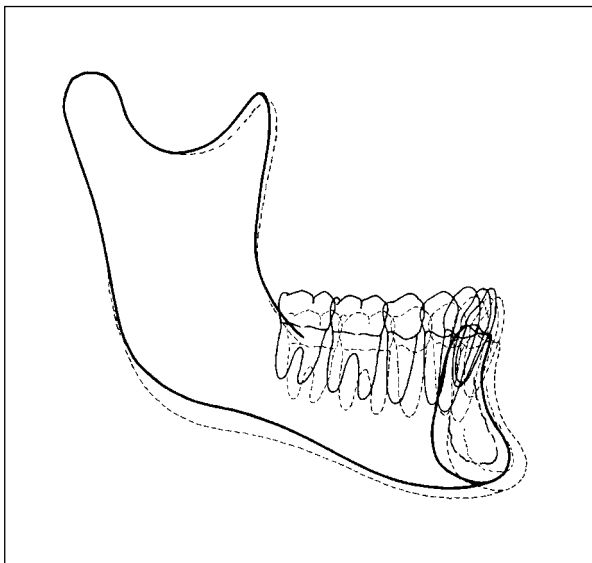


Fig 2b Mandibular positional change for males during adult growth.¹⁸ (Reprinted with permission.)

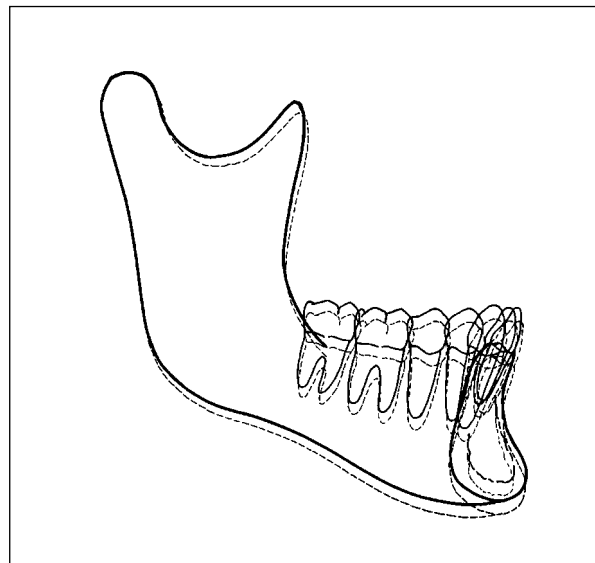


Fig 2c Mandibular positional change for females during adult growth. Note that male mandibles tend to grow more horizontally, while female mandibles grow in a more vertical direction.¹⁸ (Reprinted with permission.)

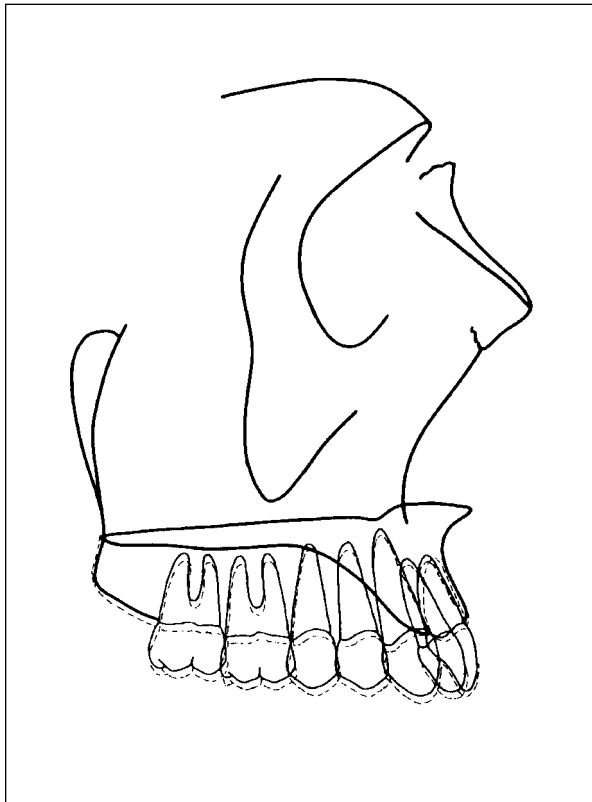
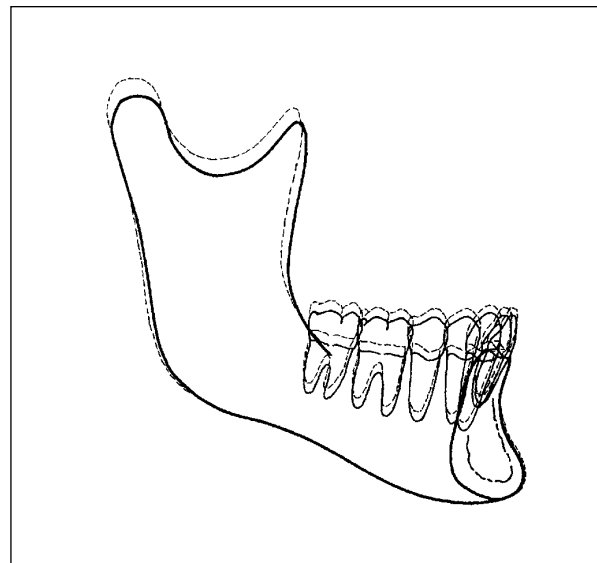
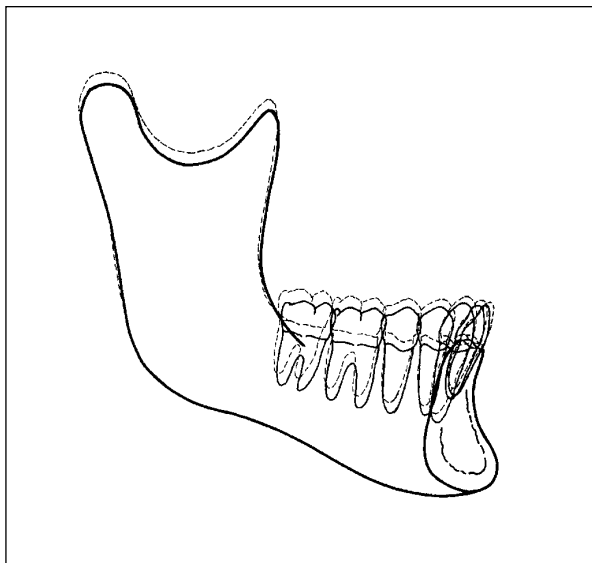


Fig 3a Maxillary dimensional changes for males and females in the aging adult. The maxillary incisors tend to upright slightly, while all of the teeth gain vertical height.¹⁸ (Reprinted with permission.)

DENTAL CHANGES

Many dental changes occur secondary to the skeletal changes, as the teeth compensate by either erupting or shifting positions. Growth and subsequent dental compensations in natural teeth surrounding a single-tooth implant will have an effect on the relative position of an implant prosthesis. The maxillary incisors in both males and females upright themselves during adulthood, with the axis appearing to be near the crown and the roots becoming more labially positioned (Fig 3a). In females, incisor inclination and protrusion increase (Fig 3b), while in males, the mandibular incisors change little (Fig 3c). This results in the interincisal angle becoming larger in males but staying the same in females. The amount of maxillary incisor uprighting is 2 to 3 degrees, with a significant amount of the change occurring between 31 and 50 years. The maxillary molars upright in both males and females, but the mandibular molars upright only in males and tip slightly mesial in females.^{18,34} The anteroposterior dental changes that compensate for adult skeletal growth are small but can be significant. Over several decades, in an adult demonstrating amounts of growth at the high end of the range, a non-compensating implant prosthesis may become progressively malaligned relative to adjacent natural teeth.



Figs 3b and 3c These tracings demonstrate dimensional changes in the aging female (*left*) and male (*right*) mandibles. Increases in ramus height are apparent, along with an increase in the vertical relationship of the mandibular teeth.¹⁸ If not compensated for by wear, the increased vertical height of the teeth could leave an implant crown out of occlusion after 2 or more decades of service. (Reprinted with permission.)

Vertical tooth changes also occur as a compensation for skeletal jaw growth (Fig 3). Only 1 study³⁶ indicated any change in anterior overbite relationship of the teeth; most studies found no change in the vertical relationship of the anterior teeth during adulthood.^{18,19,37} Increases in maxillary alveolar height average 1 to 2 mm both anteriorly and posteriorly, but some patients show no vertical change, while others demonstrate significant vertical change. Increases in mandibular alveolar vertical height are only slightly greater. The changes are continuous and progressive over the 60 years of measurement.^{18,34} While the average changes are small, a patient demonstrating maximum growth may show 2 to 3 mm of vertical increase in the natural teeth, while in another patient with little or no growth, no vertical change may occur. The effect on an implant prosthesis adjacent to natural teeth would differ between these patients, eg, in one patient the implant prosthesis would become infraoccluded by 2 to 3 mm, while in the other patient no change would occur.

Arch width also changes with age. Inter canine width increases significantly up to approximately 13 years of age³⁶ and then tends to decrease, but the decrease is generally small, being no more than 0.5 to 1.0 mm over a 20-year span.³⁷⁻³⁹ Increases in arch width would probably have little impact on a single-tooth prosthesis adjacent to natural teeth.

Arch depth and length also decrease with adult growth and aging and are associated with increased crowding. Decreases as great as 1.6 mm^{37,38} and as little as 0.1 mm in the maxillary arch and 0.6 mm in the mandibular arch³⁹ have been reported. Decreases in anterior arch perimeter as great as 2.5 mm over 10 years have been reported.⁴⁰ These decreases result in an increase in the curve of Spee³⁷ and crowding. Lundstrom³⁸ studied individuals at 19 years of age and again at 32 years and calculated the chances of increased crowding during this time at 50% in the maxilla and 85% in the mandible. Bishara et al¹⁹ found that crowding increased from mid-adolescence to mid-adulthood by 2.7 mm in the mandible and 1.9 mm in the maxilla in males and 3.5 mm in the mandible and 2.0 mm in the maxilla in females. Thus, the net result of the changes seen in the dentition during aging and adult growth does have a significant effect on the dentition in the form of crowding. Because of these changes, arch form changes to one that is more square (shorter and broader) with aging.³⁷ Increased crowding and changes in arch form could have a significant effect on a single-tooth implant in a patient who undergoes maximum growth changes, resulting in an implant crown that is out of alignment with adjacent natural teeth.

EFFECTS OF ADULT GROWTH AND AGING ON THE SINGLE-TOOTH IMPLANT

The effects of growth and aging on the single-tooth adult implant are not as significant as those seen in children or adolescents. Whereas the effects of growth in children or adolescents may be so significant that removal and replacement of the implant is required, no such dramatic changes are seen in adults. Timing and individual variation (Fig 4), however, remain a critical factor. Although it is common to consider patients over 21 years of age as adults, this may not be true for all males with respect to facial growth. Some males show substantial amounts of growth up to 25 years of age, while females are generally at adult growth rates by 17 years. Hence, most males are questionable candidates for implants until they near their 25th birthdays. In females, some later growth may be seen as a result of post-fertilization stimulation; however, the amount of growth appears to be relatively small and would probably result in no more than 1 mm of relative intrusion of the implant. In a worst-case scenario, vertical mandibular growth and the accompanying mandibular incisor protrusion might result in a single-tooth implant that was initially well-positioned becoming vertically deficient and 2 to 3 mm lingual to the natural teeth after 2 or more decades. This would not be true for all females, but if a mandibular incisor implant in a female who has had a number of children is out of occlusion and alignment, this may be a possible explanation.

Aging of the face includes not only the sagging and wrinkles commonly associated with aging, but also elements of true growth. Effects on the dentition, while small, may become significant, such as decreased visibility of the maxillary incisors and increased visibility of the mandibular incisors as the individual ages. Even though the average change in the maxillary incisor exposure is relatively minor (about 1 mm), it may be a reason to create slightly increased exposure of an anterior tooth, if appropriate. Fortunately, lengthening of the upper lip is partially compensated for by continued eruption (increase in alveolar height) in the maxilla. However, this very increase in alveolar height may have an impact on the vertical position of an anterior single-tooth implant over 2 or 3 decades. The lack of change of an implant adjacent to natural teeth that are erupting and uprighting over time may create an implant crown that is shorter and at a slightly different angulation than adjacent natural teeth. An implant replacing a mandibular incisor may be the most affected. Not only are the teeth changing slightly in a vertical direction, but also, in females,

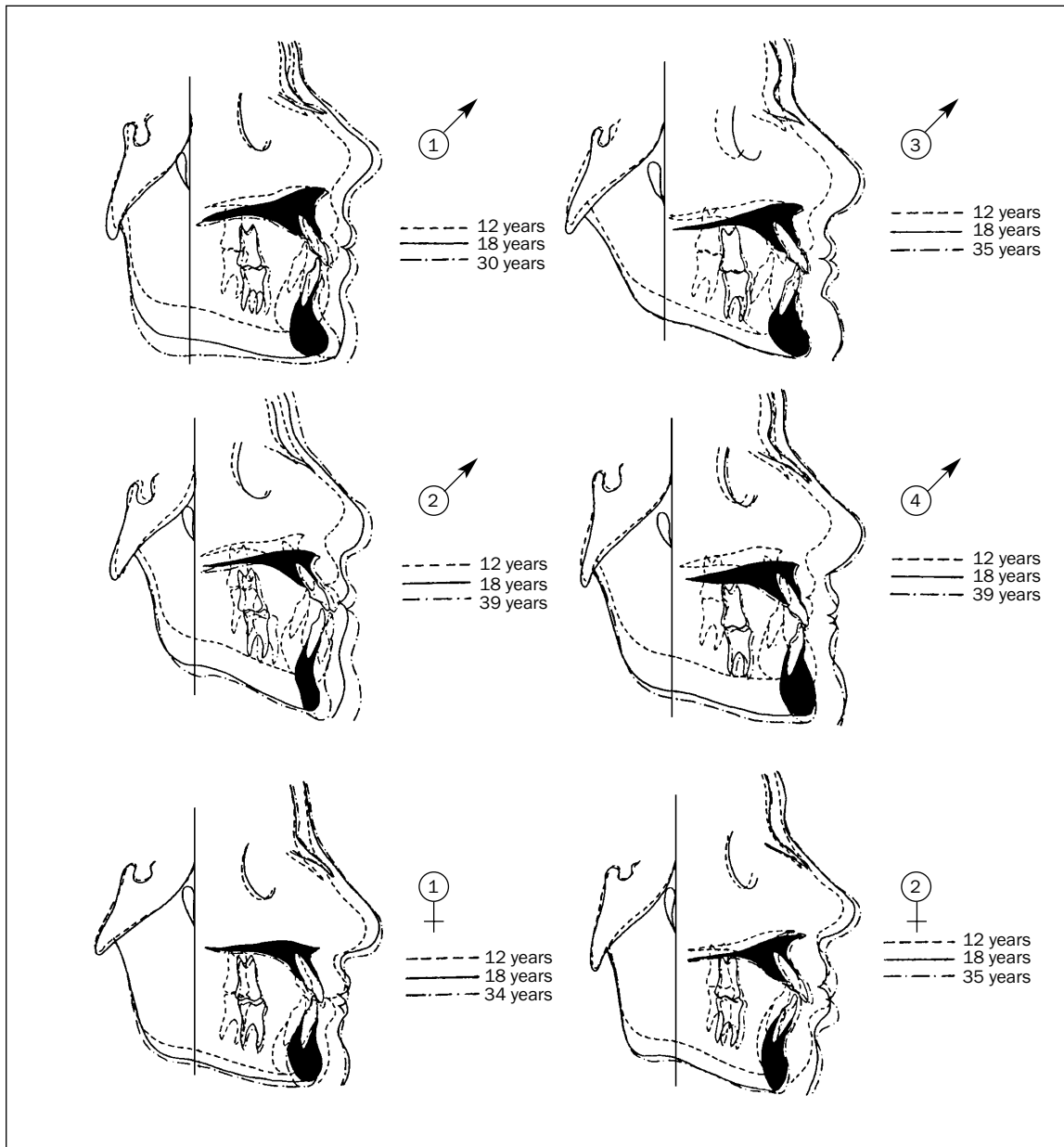


Fig 4 Tracings of 6 different individuals, which demonstrate the great variety in the amount and direction of growth. All individuals demonstrated significant growth between adolescence and young adulthood; however, the amount of growth during adulthood varied.²³ Numbers inside male/female symbols indicate patient numbers in the study. (Reprinted with permission from the American Journal of Orthodontics and Dentofacial Orthopedics.)

the natural teeth may be becoming slightly more protrusive. Combined with the tendency for mandibular incisor crowding over time, the implant crown may, over 2 or more decades, become progressively malaligned relative to adjacent teeth.

In the posterior of the mouth, changes would be more subtle. Over 2 or more decades of implant use, the implant crown may become slightly out of occlusion. This change would not be the result of

any change in the implant, but rather a result of the adjacent teeth developing in a vertical direction while the implant remains stationary. The amount of change would vary greatly between individuals, depending on the amount of adult change.

An additional confounding variable in the interpositional stability of the single-tooth implant with adjacent teeth is tooth wear. Wear of the natural dentition—either slow physiologic wear or more

rapid pathologic wear—can mitigate or even reverse the effects of adult growth. Attrition, abrasion, and erosion can all severely change the relative position of the incisal or occlusal surfaces of teeth. Acute episodes of erosive wear, which affect natural enamel and dentin at a far greater rate than the implant prosthesis restorative materials, can result in destructive occlusal prematurities on the implant-supported prosthesis. A recent study of 54 adults with advanced occlusal tooth wear revealed that the rate of dental wear exceeded the rate of compensatory tooth eruption and dentoalveolar bone growth, resulting in an anterior rotation of the mandible and a reduction in lower anterior face height.⁴¹ Dental wear is a cumulative record of both functional and parafunctional wear and is extremely variable. Studies have shown that lateral wear changes can show significant clinical differences over a 10-year period.⁴² Turner and Missirlian⁴³ described the severely worn dentition and compromise of restorative spaces that result from such wear. The single-tooth implant placed in this environment would not be expected to react physiologically as positively as might a natural tooth with a protective mechanism mediated by the periodontal membrane. These sometimes antagonistic forces of excessive wear and adult growth followed over the anticipated length of service of a dental implant can complicate treatment planning, and they need to be understood by the clinician to assist in the understanding of potential positional anomalies in the long-term maintenance of the dental implant.

The single-tooth implant, particularly in the incisor area, usually is cement-retained. In light of the foregoing discussion, retrievability of the single-tooth implant might prove to be helpful in long-term esthetic and physiologic maintenance. Continued progress is being made on achieving more optimal properties of implant cements. Innovative techniques using set screws for primary retention⁴⁴ or as retrieving screws to facilitate removal of a cementable restoration have been reported.⁴⁵ The use of set screws in the anterior is difficult, however, because of the potential for overcontouring the final restoration.

SUMMARY

All of the effects of adult growth and aging are subtle changes that occur very slowly. The changes affect the implant prosthesis over decades rather than years. In the exceptional patient who exhibits large amounts of adult growth, the effects may be seen much earlier and to a significant extent. The

knowledge that adult growth occurs and can be substantial in some patients may help to explain positional anomalies as single-tooth implants are in place for longer and longer times. Pretreatment patient counseling may be appropriate to explain the need for implant crown modification or replacement after 2 or more decades as a result of the positional changes of adult growth. Techniques for easing implant crown modification must be explored along with attention to and reporting of long-term implant-supported prosthesis changes relative to adjacent natural teeth.

REFERENCES

1. Adell R, Eriksson B, Lekholm U, Brånemark P-I, Jemt T. A long-term follow-up study of osseointegrated implants in the treatment of the totally edentulous jaw. *Int J Oral Maxillofac Implants* 1990;5:347-359.
2. Albrektsson T. A multicenter report of osseointegrated oral implants. *J Prosthet Dent* 1988;60:75-84.
3. Spear MS, Mathews DM, Kokich VG. Interdisciplinary management of single-tooth implants. *Semin Orthod* 1997; 3:45-72.
4. Walther W, Klemke J, Worle M, Heners M. Implant-supported single tooth replacements: Risks of implant and prosthesis failure. *J Oral Implantol* 1996;22:236-239.
5. Henry PJ, Laney WR, Jemt T, Harris D, Krogh PH, Polizzi G, et al. Osseointegrated implants for single-tooth replacement: A prospective 5-year multicenter study. *Int J Oral Maxillofac Implants* 1996;11:450-455.
6. Avivi-Arber L, Zarb GA. Clinical effectiveness of implant-supported single tooth replacement: The Toronto study. *Int J Oral Maxillofac Implants* 1996;11:311-321.
7. Bender MA. Posterior implant-supported single crowns: A new treatment approach. *Int J Dent Symposia* 1994;2:65-69.
8. Rosenquist B, Grenthe B. Immediate placement of implants into extraction sockets: Implant survival. *Int J Oral Maxillofac Implants* 1996;11:205-209.
9. Klineberg I, Henry P. A review of educational developments with Brånemark osseointegrated oral implants in Australia and New Zealand 1992-1994. *Aust Prosthodont J* 1995; 9(suppl):49-53.
10. Meffert RM. Issues related to single-tooth implants. *J Am Dent Assoc* 1997;128:1383-1390.
11. Kucey BK. Implant placement in prosthodontics practice: A five-year retrospective study. *J Prosthet Dent* 1997;77: 171-176.
12. Andersson B, Odman P, Carlsson GE. A study of 184 consecutive patients referred for single-tooth replacement. *Clin Oral Implants Res* 1995;6:232-237.
13. Oesterle LJ, Cronin RJ, Ranly DM. Maxillary implants and the growing patient. *Int J Oral Maxillofac Implants* 1993;8: 377-386.
14. Cronin RJ, Oesterle LJ, Ranly DM. Mandibular implants and the growing patient. *Int J Oral Maxillofac Implants* 1994;9:55-62.
15. Odman J, Gröndahl K, Lekholm U, Thilander B. The effect of osseointegrated implants on the dentoalveolar development: A clinical and radiographic study in growing pigs. *Eur J Orthod* 1991;13:279-286.

16. Brugnolo E, Mazzocco MD, Cordioli G, Majzoub Z. Clinical and radiographic findings following placement of single-tooth implants in young patients—Case reports. *Int J Periodontics Restorative Dent* 1996;16:421–433.
17. Smith RA, Vargervik K, Kearns G, Bosch C, Koumjian J. Placement of an endosseous implant in a growing child with ectodermal dysplasia. *Oral Surg Oral Med Oral Pathol* 1993;75:669–673.
18. Behrents RG. Growth in the Aging Craniofacial Skeleton [monograph 17 and 18, Craniofacial Growth Series]. Ann Arbor: The University of Michigan, 1985.
19. Bishara SE, Treder JE, Jakobsen JR. Facial and dental changes in adulthood. *Am J Orthod Dentofac Orthop* 1994;106:175–186.
20. Forsberg CM. Facial morphology and aging: A longitudinal cephalometric investigation of young adults. *Eur J Orthod* 1979;1:15–23.
21. Nanda RS, Meng HP, Kapila S, Goorhuis J. Growth changes in the soft tissue facial profile. *Angle Orthod* 1990;60:177–190.
22. Bishara SE, Peterson LC, Bishara EC. Changes in facial dimensions and relationships between the ages of 5 and 25 years. *Am J Orthod Dentofac Orthop* 1984;85:238–252.
23. Formby WA, Nanda RS, Currier GF. Longitudinal changes in the adult facial profile. *Am J Orthod Dentofac Orthop* 1994;105:464–476.
24. Larrabee WF, Caro I. The aging face—Why changes occur, how to correct them. *Postgrad Med* 1984;76:37–39,42–46.
25. Ellis DAF, Ward DK. The aging face. *J Otolaryngol* 1986;15:217–223.
26. Bhawan J, Andersen W, Lee J, Labadie R, Solares G. Photoaging versus intrinsic aging: A morphologic assessment of facial skin. *J Cutan Pathol* 1995;22:154–159.
27. Susanne C. Aging, continuous changes of adulthood. In: Johnston FE, Roche AF, Susanne C (eds). *Human Physical Growth and Maturation*. New York: Plenum Press, 1978.
28. Converse JM. *Reconstructive Plastic Surgery*, ed 2. Philadelphia: WB Saunders Co, 1977.
29. Ellis DAF, Ward DK. The aging face. *J Otolaryngol* 1986;15:217–223.
30. Gonzalez-Ulloa M, Simonia F, Flores E. The Anatomy of the Aging Face. *Transactions of the Fifth International Congress of Plastic and Reconstructive Surgery*, ed 1. London: Butterworth and Co Ltd, 1971.
31. Krmpotic-Nemanic J, Kostovic I, Nemanic G. Morphological and histological changes responsible for the droop of the nasal tip in advanced age. *Acta Otolaryngol* 1971;71:278–281.
32. Patterson CN. The aging nose: Characteristics and correction. *Otolaryngol Clin North Am* 1980;13:275–288.
33. Sarnes KV, Solow B. Early adult change in the skeletal and soft-tissue profile. *Eur J Orthod* 1980;2:1–12.
34. Forsberg CM, Eliasson S, Westergren H. Face height and tooth eruption in adults—A 20-year follow-up investigation. *Eur J Orthod* 1991;13:249–254.
35. Isreal H. Recent knowledge concerning craniofacial aging. *Angle Orthod* 1973;43:176–184.
36. Bishara SE, Jakobsen JR, Treder J, Nowak A. Arch width changes from 6 weeks to 45 years of age. *Am J Orthod Dentofac Orthop* 1997;111:401–409.
37. Harris EF. A longitudinal study of arch size and form in untreated adults. *Am J Orthod Dentofac Orthop* 1997;111:419–427.
38. Lundstrom A. Changes in crowding and spacing of the teeth with age. *Dent Pract* 1969;19:218–224.
39. Bishara SE, Treder JE, Damon P, Olsen M. Changes in the dental arches and dentition between 25 and 45 years of age. *Angle Orthod* 1996;66:417–422.
40. Bondevik O. Changes in occlusion between 23 and 34 years. *Angle Orthod* 1998;68:75–80.
41. Kiliaridis S, Johansson A, Haraldson T, Omar R, Carlsson G. Craniofacial morphology, occlusal traits, and bite force in persons with advanced occlusal tooth wear. *Am J Orthod Dentofac Orthop* 1995;107:286–292.
42. Seligman DA, Pullinger AG. The degree to which attrition in modern society is a function of age and of canine contact. *J Orofac Pain* 1995;9:266–275.
43. Turner KA, Missirlan DM. Restoration of the extremely worn dentition. *J Prosthet Dent* 1994;52:467–474.
44. Chiche G, Kokich VG, Caudill R. Diagnosis and treatment planning of esthetic problems. In: Chiche G, Pinault A (eds). *Esthetics of Anterior Fixed Prosthodontics*. Chicago: Quintessence, 1994:48–50.
45. Chee WL, Torbati A, Albouy JP. Retrievable cemented implant restorations. *J Prosthodont* 1998;7:120–125.